

Acoustic Neuroma: A Basic Overview

IMPORTANT POINTS TO KNOW ABOUT AN ACOUSTIC NEUROMA:

- An acoustic neuroma is a benign tumor.
- It is usually slow growing and expands at its site of origin.
- The most common first symptom is hearing loss in the tumor ear.
- The cause is unknown.
- A large tumor pushes on the surface of the brain but does not grow into the brain tissue.
- Continued tumor growth can be life threatening.
- The treatment options are observation, surgical removal or radiation.

WHAT IS AN ACOUSTIC NEUROMA?

An acoustic neuroma (sometimes termed a vestibular schwannoma or neurolemmoma) is a benign (non-cancerous) tissue growth that arises on the eighth cranial nerve leading from the brain to the inner ear. This nerve has two distinct parts, one part associated with transmitting sound and the other with sending balance information to the brain from the inner ear. These pathways, along with the facial nerve, lie adjacent to each other as they pass through a bony canal called the internal auditory canal. This canal is approximately 2 cm (0.8 inches) long and it is here that acoustic neuromas originate from the sheath surrounding the eighth nerve. The facial nerve provides motion of the muscles of facial expression.

Acoustic neuromas usually grow slowly over a period of years. They expand in size at their site of origin and when large can displace normal brain tissue. The brain is not invaded by the tumor, but the tumor pushes the brain as it enlarges. The slowly enlarging tumor protrudes from the internal auditory canal into an area behind the temporal bone called the cerebellopontine angle. The tumor now assumes a pear shape with the small end in the internal auditory canal. Larger tumors can press on another nerve in the area (the trigeminal nerve) which is the nerve of facial sensation. Vital functions to sustain life can be threatened when large tumors cause severe pressure on the brainstem and cerebellum part of the brain. Tumors are typically described as small (less than 1.5 cm), medium (1.5 cm to 2.5 cm) or large (more than 2.5 cm).

ARE ACOUSTIC NEUROMAS HEREDITARY?

No. Although there is an inheritable condition called neurofibromatosis type 2 which can lead to acoustic neuroma formation in some people, most acoustic neuromas occur spontaneously without any evidence of an inheritable pattern.

HOW OFTEN DO ACOUSTIC NEUROMAS OCCUR?

Most recent publications suggest that the incidence of acoustic neuromas is rising. This is because of advances in MRI scanning both on incidental scans and for patients experiencing symptoms. Studies in Denmark, published in 2004, show the incidence is 17.4 per million or close to 2 persons per 100,000. Most acoustic neuromas are diagnosed in patients between the ages of 30 and 60.

SYMPTOMS OF ACOUSTIC NEUROMA

Early symptoms are easily overlooked, thus making diagnosis a challenge. There usually are symptoms, however, pointing to the possibility of an acoustic neuroma. The first symptom in 90% of those with a tumor is a reduction in hearing in one ear, often accompanied by ear noise or tinnitus. The loss of hearing is usually subtle and worsens slowly, although occasionally a sudden loss of hearing is noted. There may be a feeling of fullness in the affected ear. These early symptoms are sometimes mistaken for normal changes of aging, and diagnosis is often delayed.

Since the balance portion of the eighth nerve is where the tumor arises, unsteadiness and balance problems may occur during the growth of the neuroma. The remainder of the balance system sometimes compensates for this loss, and no imbalance will be noticed. Larger tumors can press on the trigeminal nerve, causing facial numbness and tingling - constantly or intermittently. Increase of intracranial pressure may be experienced with headaches, clumsy gait and mental confusion. This is a life-threatening complication requiring urgent treatment.

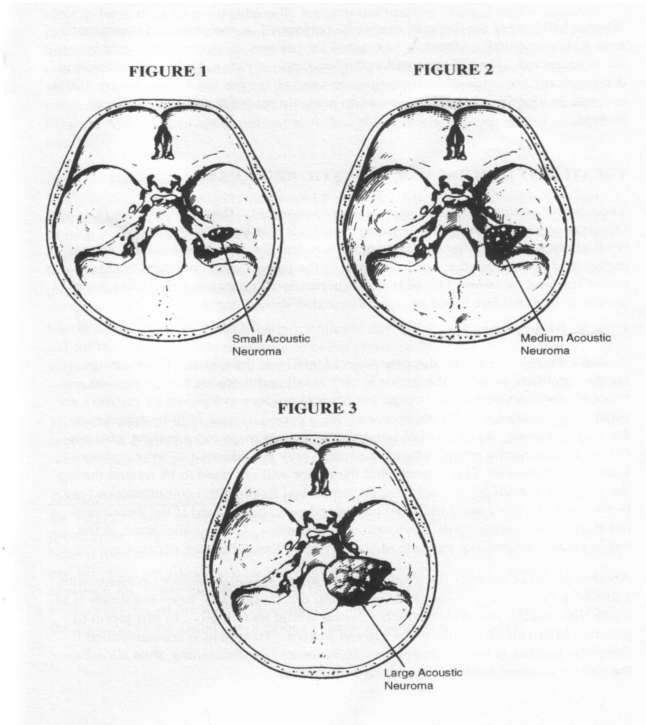
IDENTIFYING THE TUMOR

Advances in medicine have made possible the identification of small acoustic neuromas; that is, those still confined to the internal auditory canal. Routine auditory tests may reveal a loss of hearing and speech discrimination (the patient can hear sound in that ear, but cannot understand what is being said).

An audiogram should be performed to effectively evaluate hearing in both ears. This test is important to begin the diagnosis of acoustic neuroma. Magnetic resonance imaging (MRI) is the diagnostic test that is preferred for identifying acoustic neuromas. Gadolinium, an enhancing material, is required to reveal the tumor. The image formed clearly defines an acoustic neuroma if it is present. Currently, this imaging study is the preferred test for identifying acoustic neuromas.

FIGURES 1, 2, AND 3:

ACOUSTIC NEUROMA IN POSITION AS SEEN FROM ABOVE – SMALL, MEDIUM AND LARGE TUMORS IDENTIFIED:



An auditory brainstem response test (ABR, BAER, or BSER) may be done in some cases. This test provides information on the passage of an electrical impulse along the circuit from the inner ear to the brainstem pathways. An acoustic neuroma can interfere with the passage of this electrical impulse through the hearing nerve at the site of tumor growth in the internal auditory canal. This implies the possible diagnosis of an acoustic neuroma when the test is positive.

When a MRI is not available or cannot be performed, a computerized tomography scan (CT scan), with contrast, is suggested for patients in whom an acoustic neuroma is suspected. The CT scan and audiogram can provide valuable information to determine the presence of an acoustic neuroma. MRI is the "gold standard" by which diagnosis is confirmed. The technique can identify tumors only a few millimeters in diameter. Dye studies are typically done to confirm tumor and uptake with gadolinium is confirmatory.

TREATMENT OPTIONS FOR ACOUSTIC NEUROMA

There are three treatment options available to a patient. These options are:

- 1) Observation,
- 2) Microsurgical Removal and
- 3) Radiation ("radiosurgery" or "radiotherapy").

Choosing the best option is a decision that must be made by the patient and physician after careful review of the patient's age, physical health, tumor size and location. The skill and experience of the treating physician are also factors to be considered and an open discussion should occur.

1. Observation – Watch & Wait:

Acoustic neuromas may be discovered incidentally in the course of evaluating another problem, or when the tumor is very small and there are few symptoms. Since acoustic neuromas are benign tumors and produce symptoms by pressure on surrounding nerves, careful observation over a period of time may be appropriate for some patients. When a small tumor is discovered in an older patient, observation to determine the growth rate of the tumor may be indicated if serious symptoms are not present. If it appears that the tumor will not need to be treated during the patient's normal life expectancy, treatment and its potential complications may be avoided. In this case, MRI's are performed periodically, and if the tumor does not show significant growth, observation is continued. On the other hand, if the tumor shows progressive increase in size, treatment may become necessary.

Another group of patients for whom observation is indicated includes patients with a tumor in their only hearing or better hearing ear, particularly when the tumor is of a size that hearing preservation with removal would be unlikely. In this group of patients, MRI is used to follow the growth pattern. Treatment is recommended if either the hearing is lost or the tumor size becomes life-threatening, thus allowing the patient to retain hearing for as long as possible.

2. Microsurgical Tumor Removal:

A. Partial Tumor Removal:

Partial removal of an acoustic neuroma may be indicated in some patients in order to reduce the risk of complications, with the realization that further surgery may be needed in the future. Older patients with large tumors causing a threat to life may elect to have their surgeon sub-totally remove their tumor. Partial tumor removal has also been advocated in some patients who have large tumors in their only hearing ear. This surgical management will reduce the tumor in size, so that it may cause no threat to the patient's health during his or her life expectancy. This approach may greatly reduce the probability of any facial nerve dysfunction as a result of the surgery, but there is still a risk for hearing loss with partial removal. Periodic MRI studies are important to follow the potential growth rate of residual tumor.

B. Total Tumor Removal:

Many tumors can be entirely removed by surgery. Microsurgical technique and instruments, along with the operating microscope, have reduced the surgical risks of total tumor removal. Preservation of the facial nerve is the primary task for the experienced acoustic neuroma surgeon to prevent permanent facial paralysis. Preservation of hearing in the affected ear is also an important goal in patients who present with functional hearing.

Facial nerve function is electrically monitored during surgery. This is a valuable aid for the surgeon while the tumor is being removed from the facial nerve during surgery. Cochlear nerve electrical monitoring is also employed during operations when preservation of hearing is a goal.

C. Surgical Procedures:

At the last NIH Consensus Conference (1991) the best published surgical outcomes in the treatment of acoustic neuroma are related to the surgical approaches of translabyrinthine, retrosigmoid/sub-occipital and middle fossa. The approach is based on several factors such as tumor size, location, skill and experience of the surgeon, and whether or not hearing preservation is a goal. The surgeon and the patient should thoroughly discuss the reasons for a selected approach. Each of the surgical approaches has advantages and disadvantages, and excellent results have been achieved using any of the approaches.

- **Translabyrinthine Approach:** The translabyrinthine approach may be preferred by the surgical team when the patient has no useful hearing, or when an attempt to preserve hearing would be impractical. The incision for this approach is located behind the ear. It involves removing the mastoid bone and some bone in the inner ear, allowing excellent exposure of the internal auditory canal and tumor site.

This approach facilitates the identification of the facial nerve in the temporal bone prior to any removal of the tumor. The surgeon, therefore, has the advantage of knowing the location of the facial nerve prior to tumor dissection and removal. A secondary incision is needed to harvest fat from the abdomen. This is typically just above the groin area and below the belt line. Fat is the substance that is used to prevent a cerebral spinal fluid leak. The leak rates have been consistently falling in most centres experienced with this procedure.

- **Retrosigmoid/sub-occipital Approach:** This approach creates an opening in the cranium behind the mastoid part of the ear. The surgeon observes the tumor from its posterior surface, thereby seeing the tumor in relation to the brainstem. When removing large tumors through this approach, the facial nerve can be exposed by early opening of the internal auditory canal. Small tumors can be removed with hope of preserving hearing in some patients through this approach.

- **Middle Fossa Approach:** This approach is utilized primarily for the purpose of preservation of hearing. A small window of bone is removed above the ear canal to allow exposure of the

tumor from the upper surface of the internal auditory canal beyond the inner ear. This approach is practical only for small tumors.

3. Radiation:

The third treatment option for an acoustic neuroma is radiation. Stereotactic radiation therapy, referred to as "radiosurgery" (typically performed in a single session) or "radiotherapy" (typically delivered over an extended period of time in multiple doses of radiation) is a technique based on the principle that radiation delivered precisely to the tumor will arrest its growth while minimizing injury to surrounding nerves and brain tissue. This noninvasive procedure can be performed in a one-dose treatment on an outpatient basis, or in a multi-dose treatment ranging from several days to over several weeks.

In single dose treatments, many hundreds of small beams of radiation are aimed at the acoustic neuroma. This results in a high dose of radiation to the tumor and very little to any surrounding brain structures. Radiosurgery is delivered as a one-time, outpatient treatment. Many patients have been treated this way with high success rates. Facial weakness or numbness, in the hands of experienced radiosurgeons, occurs in only a small percent of cases and is usually temporary. Hearing can be preserved in many cases.

The multi-dose treatment, fractionated stereotactic radiosurgery (FSR), delivers smaller doses of radiation over a period of time, requiring the patient to return to the treatment location on a daily basis, sometimes over several weeks. Each visit only takes a few minutes and most patients are free to go about their daily business before and after each treatment session. FSR may become a more effective treatment as greater experience is gained with this technique.

The treatment team may consist of a neurosurgeon, a neurotologist, a radiation oncologist and a physicist. While in the past, conflicting reports occurred among physicians, radiosurgery has an increasing role in the management of patients with acoustic neuromas. Patients must understand that this treatment does not remove the tumor as in microsurgery, but in some cases shrinkage does occur. Further, the patient must understand that close follow up for a lifetime with MRI scanning is needed to track the results of radiosurgery. It appears that more favorable cases are those patients with small to medium size tumors, without brainstem indentation. Indeed, side effects can occur when the brainstem is irradiated, and in some cases of large tumors; radiation is contraindicated. Patients should understand there have been sporadic reports of malignant degeneration or development of new adjacent tumors after radiotherapy, but the incidence of this happening appears to be rare.

There can be confusion regarding which type of radiation device to select. The greatest number of peer reviewed articles have come from centers with Gamma Knife. Typically multiple shots of radiation are configured to create a three dimensional volume of radiation that conforms to the tumor precisely. The source for the radiation is cobalt 60 and typically that dose is 11 to 14 Gy, depending on hearing status and the patient's condition. The patient wears a stereotactic frame that provides accuracy and

precision. The radiation is usually administered once over 30-50 minutes depending on the specific tumor.

Linear accelerator radiosurgery uses a conventional radiotherapy machine to deliver radiation to the target. Patients are placed in a stereotactic head frame to allow precise treatment. Multiple isocenter techniques (the precise mathematical location where a radiation dose is aimed) are used to develop a conformal plan.

Fractionated techniques have their advocates as well. The rationale for this technique may be an attempt to preserve hearing. At this time more long term studies are needed in all types of radiosurgery to confirm this statement. Problems come with lack of follow-up or standard protocol reporting of results.

Just like microsurgery, patients are advised to inquire about a particular center's experience with acoustic tumors. The longer the center has been active, published, and greater number of patients treated is an appropriate way to judge the potential outcome. No center can guarantee the outcome despite statements of the "latest and greatest technology".

CAUSE OR EPIDEMIOLOGY OF ACOUSTIC NEUROMA

Most patients inquire, now did this tumor occur? While many theories exist, studies have hinted at exposure to loud noise on a consistent basis. There are even controversies on hand held cellular phones. Whether or not the radiofrequency radiation has anything to do with their formation, remains to be seen. Other studies mention the prior exposure to head and neck radiation, and a concomitant history of having had a parathyroid adenoma (tumor found in proximity to the thyroid gland controlling calcium metabolism).

NEUROFIBROMATOSIS (NF2)

NF2, a genetic disorder, occurs with a frequency of 1 in 30,000 to 1 in 50,000 births. The most perplexing problem are those patients who are slowly losing their hearing due to bilateral tumors. Here a decision about the timing and management of patients with NF2 lesions is notoriously difficult. The trend is to postpone surgery until hearing begins to deteriorate. But studies by Derald E. Brackman, M.D. and colleagues have the opinion to take a proactive approach in bilateral tumors in which hearing is still present. They have reviewed individuals who have undergone middle fossa surgery and found that when tumors are less than 1.5 centimeters in size, surgery may be appropriate. Hearing preservation was obtained in 70% of cases. The situation is much more complex for individuals with NF2 and only one hearing ear—conservatism and observation may be more appropriate here. Stereotactic radiosurgery may not have the same effect on the NF2 patient as in patients with unilateral

sporadic tumors. Recent studies have shown that these individuals may have more tumors that are resistant to radiation, due to the cell type.

AFTER TREATMENT

Surgical removal of an acoustic neuroma is a complex and delicate process. In general, the smaller the tumor at the time of surgery, the fewer complications. The hospital stay after microsurgery is getting shorter, generally three to five days on the average, with approximately four to six weeks suggested for recovery. Longer stays may be necessary for patients with large tumors. Patients routinely spend at least one night after surgery in the intensive care unit for care and observation. The time after surgery can be filled with days or perhaps weeks of new sensations. There is usually head discomfort and fatigue. Some patients may experience emotional lows after major surgery, and those lows are believed to be a part of the natural healing process.

Even when tumor removal has been accomplished, there is a small chance of tumor recurrence. Therefore, a follow-up MRI after tumor removal should be performed within one to five years.

In radiosurgery patients, tumor cell growth is not arrested immediately. Some tumor cells die in a matter of weeks, but others do so more gradually, generally 6-18 months after treatment. This treatment usually arrests the growth of the tumor and some tumors will shrink in size, but the tumor does not disappear. Follow-up studies are important because some tumors will continue to grow after this treatment or at some time in the future. It appears that the tumor growth will be controlled in a high percentage of cases. It is not possible to determine which tumors will continue to grow larger after radiation; therefore, periodic MRI's are necessary throughout life.

RESIDUAL PROBLEMS AFTER TREATMENT

Some, but not all, patients experience short and long term problems after surgery and the patient should be aware of the complications that exist. Besides hearing loss, the most common problems are excessive eye dryness, balance difficulties, tinnitus, facial weakness, and headaches. Separate booklets are available from ANAC on these topics. (See an order form at the back of this booklet.) Some patients experience cerebrospinal fluid leak (CSF) through the incision or nose, and this occurrence should be reported to the surgeon promptly.

Patients with large tumors are likely to have significant hearing loss and are in a situation where preservation of hearing is unrealistic or impossible. In most cases, the percentage of patients in whom hearing can be preserved increases with decreased tumor size. Patients with partially preserved hearing may benefit from a hearing aid. If there is total hearing loss, the patient might want to try one of the many hearing devices available. Some use a CROS (contralateral routing of sound) hearing aid

system, whereby a microphone type of hearing aid on the non-hearing ear routes the sound to the normal hearing ear, providing some hearing from the deaf side. The sound may also be conducted via the bone with a bone-anchored hearing aid such as the BAHA.

Tinnitus or "ear noise" is common in acoustic neuroma patients, and preservation of hearing does not eliminate the tinnitus. Removal of the hearing nerve with the tumor, however, does not increase the likelihood that the tinnitus will also disappear.

Radiosurgery, because it is an outpatient treatment performed under local anesthesia, is not associated with most of the complications of open surgery—such as infection, CSF leak, stroke, or systemic problems. Occasionally, patients develop facial numbness, facial weakness or deafness on the side of treatment. This typically occurs between 6-18 months after treatment, and is usually temporary, except for the hearing loss.

GLOSSARY OF TERMS

ACOUSTIC: Pertaining to hearing.

ACOUSTIC NEUROMA: Benign tumor of the eighth cranial nerve.

AUDIOGRAM: A chart of hearing acuity recorded during hearing tests.

BENIGN: Not malignant - does not spread to other parts of the body.

BILATERAL: Pertaining to both sides of the body.

BRAINSTEM: Connects the upper brain to the spinal cord - less than three inches (7.6 cm) long (pons is one part of the brain stem).

CENTIMETER (cm): .394 inch (2.54 cm equals one inch) - Ten millimeters equal one centimeter.

CEREBELLOPONTINE ANGLE: Space bounded by the petrous bone, brain stem, and cerebellum, and through which cranial nerves six (VI), seven (VII), eight (VIII), nine (IX), ten (X), and eleven (XI) pass.

CEREBELLUM: Located behind the brain stem, extending from the brain stem out toward each mastoid bone. It carries 11% of the brain's weight and controls muscular coordination (see Figure 4).

CRANIAL NERVES: The cranial nerves control the sensory and muscle functions around the eyes, face, and throat. There are two sets each of twelve cranial nerves. Each set involves one side of the body.

CROSS HEARING AID: Contralateral Routing of Sound, a CROS hearing aid system, can be used with single-sided deafness. It receives sound on the deaf side, amplifies it, and carries it to the good ear.

CSF (cerebrospinal fluid): A watery fluid, continuously being produced and absorbed, which flows in the ventricles (cavities) within the brain and around the surface of the brain and spinal cord.

CT SCAN (Computerized tomography): A special X-ray test which creates a cross-sectional picture of any part of the body. This X-ray can distinguish among tissue, fluid, fat, and bone, and, after intravenous injection of a dye, will show an acoustic neuroma unless the tumor is very small.

FSR (Fractionated Stereotactic Radiation): Fractionated stereotactic radiation refers to any focused radiation treatment that requires more than one treatment delivery session. Many different dosing schedules are under investigation.

GADOLINIUM: A contrast material given at the time of MRI which concentrates in the tumor and makes it more visible.

GAMMA KNIFE: The Gamma Knife is a radiosurgical machine that contains 201 separate radioactive cobalt sources. The radiation beams from each source (gamma rays) are focused together at the tumor.

LINAC: Linear accelerator is a radiosurgical machine that produces radiation electronically. These radiation beams are called X-rays. LINACs are also commonly used for conventional radiation treatment of tumors elsewhere in the body.

MAGNETIC RESONANCE IMAGING (MRI): A body imaging system employing a magnet that surrounds the patient. A magnetic field causes small harmless movement of the atoms in the area of the body being studied. A low energy radio wave is then passed through the same area and the minute change this imparts to the atoms in the magnetic field causes signals to be emitted which are picked up and analyzed by modern computer technology. An image of the tissue is produced in clear detail. Copies of MRI's are available to patients.

MIDDLE FOSSA: Surgical approach to an acoustic neuroma primarily used for the purpose of hearing preservation.

NEUROFIBROMATOSIS: A familial condition characterized by developmental changes in the nervous system, muscles, bones, and skin—the central form (Neurofibromatosis Type 2 – NF2) may produce bilateral acoustic neuromas.

NEUROMA: Benign growth originating on a nerve.

PEACOCK RADIATION: The Peacock device is an attachment to the LINAC radiosurgery system that allows complex radiation beam shapes to be generated.

PONS: Located at the base of the brain in front of the cerebellum. This section of the cranium is a mass of nerve tissue that coordinates the activities of the various lobes of the brain.

POSTERIOR FOSSA: The cavity in the back part of the skull that contains the cerebellum, brain stem, and cranial nerves 5-12.

PROTON RADIATION: Proton radiation differs from the photon radiation produced by both the Gamma Knife and LINAC systems. Proton beams have a unique physical property that allows them to be sharply focused within a tumor. They are theoretically advantageous for radiosurgery treatment. Proton therapy is usually not indicated for acoustic neuroma.

RADIOSURGERY (STEREOTACTIC RADIOSURGERY): A technique based on the principle that a single or fractionated dose of radiation delivered precisely to a small area will arrest or kill the tumor, while minimizing injury to surrounding nerves and brain tissue and/or function. Typically this is

performed in a single session.

RADIOTHERAPY: Typically radiation treatment delivered over an extended period of time with multiple doses.

RETROSIGMOID/SUB-OCCIPITAL: Surgical approach to an acoustic neuroma creating an opening in the cranium behind the mastoid part of the ear.

SENSORINEURAL HEARING LOSS: Deafness caused by failure of the acoustic nerve.

SHUNT: A tube implanted in the cranium to balance the flow of cerebrospinal fluid and used in the treatment of hydrocephalus.

TINNITUS: A noise produced in the inner ear, such as ringing, buzzing, roaring, clicking, etc.

TRANSLABYRINTHINE: Surgical approach to an acoustic neuroma through the mastoid bone and inner ear (labyrinth).

UNILATERAL: Involving only one side.

VERTIGO: Dizziness - a symptom sometimes caused by an acoustic neuroma.

VESTIBULAR: Associated with the balance system.

This booklet ("A Basic Overview") was created and originally published by The Acoustic Neuroma Association of Cumming, GA, USA (ANAUSA) in February 2007. It has been reviewed by Dr. Abhijit Guha of the Medical Advisory Board of the Acoustic Neuroma Association of Canada (ANAC), and has been adapted and printed with permission from ANAUSA.

Printed by ANAC in Canada 2008

WHAT IS THE ACOUSTIC NEUROMA ASSOCIATION OF CANADA?

In early 1983, Virginia Garossino, Velma Campbell and Linda Gray met for the first time. The three Edmonton women had had acoustic neuroma surgery within a year of each other, and had encountered individual sets of difficulties and recoveries. They discovered early in their search that there wasn't a support or information system in place for Canadians dealing with this unique tumor. Along with husbands Dick Garossino and George Campbell, the three agreed to establish a charitable organization to meet those needs and allow others across the country to share experiences and information.

The vision was of an organization of national scope with a distinguished medical advisory board. The mission was to decrease diagnostic time and improve treatment. The focus was simple and succinct: give others what had not been available for them—relieve the pain, the anxiety, and the tumultuous search for answers and information. The founders realized that success would be totally dependent on enthusiastic, knowledgeable volunteer work from recovering ANs and their families and health professionals. In March 1984, their dream was realized with the incorporation of the Acoustic Neuroma Association of Canada, a national charitable organization with the vision statement, "The Hope is Recognition and Treatment."

*ANAC recommends treatment from a medical team
with substantial acoustic neuroma experience.*

OTHER ANAC PUBLICATIONS (free to members)

Booklets available:

1. "A Basic Overview"
2. "Diagnosis - What Next?"
3. "Eye Care"
4. "The Facial Nerve: Possible Damage and Rehabilitation"
5. "Headache"
6. "Improving Balance"

To order any of these publications you may contact us by phone at 1-800-561-2622; e-mail info@anac.ca.